

Technique to reduce failure with corneal stromal tattoo in patients with symptomatic laser peripheral iridotomy

Emma C. Davies, MD; Haijirah N. Saeed, MD; Roberto Pineda II, MD

Cornea and Refractive Surgery Service, Massachusetts Eye and Ear Infirmary, Harvard Medical School

Abstract

Purpose. This study presents two cases of persistent glare symptoms after laser peripheral iridotomy despite the patients undergoing corneal stromal tattooing with black ink placed in a manually constructed stromal pocket. Possible reasons as to why each case resulted in treatment failure are described along with a technique to reduce such failures.

Methods. The study design is a retrospective report of two cases of corneal stromal tattooing after symptomatic laser peripheral iridotomy.

Results. In both cases, failure to resolve glare symptoms was attributed to patchy pigmentation in the corneal stromal pocket that was highlighted only with retro-illumination at the slit lamp.

Conclusions. The method proposed to reduce failures is verifying with retro-illumination for defects in a corneal tattoo as a method to reduce failures.

Introduction

The history of corneal tattooing dates back to 150 AD when Roman physician and philosopher, Galen of Pergamum, first described a method of cauterizing the corneal surface with a heated stilet and then staining with gallnut and copper sulfate to treat opacities of the

eye.¹ After Galen's reference to corneal tattooing, the practice is not mentioned until 1869 when oculoplastic surgeon Louis Von Weckner introduced a new method. He inserted black ink, India ink, or China ink into the cornea via a grooved needle to create a "pupil" in leukomatous corneas.² Despite its ancient history, cornea tattooing is still used to this day for cosmesis of corneal scars and for symptomatic reduction of glare in patients with aniridia, albinism, large colobomas, and peripheral iridotomies.³

There are several different tattooing methods that exist, with variations on pigmentation delivery and type of pigment used. Pigmentation may be placed either by multiple stromal micropunctures or by creating a stromal pocket, either created manually or assisted by femtosecond laser, to contain the pigment.⁴ Many different types of pigmentation exist and are classified into two broad categories, the chemical method and non-metallic dyes. The chemical method uses a metallic substance, most commonly platinum and gold chloride, to trigger a chemical reaction to precipitate pigmentation in the cornea.⁵ Non-metallic dyes, such as India ink, Chinese ink, lamp black, organic dyes, and uveal pigment from animal eyes, are used to color the cornea directly.⁵ Pigmentation with the chemical method is considered easier and more efficient but tends to fade faster, particularly with

Correspondence:

Emma C. Davies, MD
Massachusetts Eye and Ear Infirmary
Harvard University
Boston, MA
E-mail: emma_davies@meei.harvard.edu
Phone: (617) 573-4393

Conflict of Interest: The authors report no conflicts of interest.

Contributions: All authors contributed equally.

Accepted for Publication: May, 2018

This work is licensed under a Creative Commons Attribution Non-Commercial 3.0 License (CC BY-NC 3.0).

©Copyright Davies et al., 2018.

Licensee Ophthosience Publishers, USA

microstromal puncture, than pigmentation with non-metallic dyes.⁵

Case Reports

The corneal tattooing technique utilized in the current case reports of patients with a peripheral iridotomy complicated by glare is detailed below. After the eye is prepped and draped in the usual sterile ophthalmic fashion, the eye is anesthetized with lidocaine gel and a lid speculum is placed to obtain adequate exposure. A peripheral corneal stromal pocket is made using a crescent blade overlying the region of the iris defect. Several drops of sterile black ink (Black dye #1, Huck Spalding, NY) are placed in the stromal pocket using a large bore IV cannula (20 gauge) and the ink is smoothed across the pocket with the cannula tip to achieve, ideally, uniform coverage. The stromal pocket is closed, and the eye is irrigated copiously with balanced salt solution. The patient is then escorted to a slit lamp where retro-illumination through the pupil is used to determine any residual light penetration through the stromal tattoo. If retro-illumination demonstrates defects in the pigmentation, additional placement of dye in the corneal stromal pocket is performed for complete obscuration of the defect.

The first case is a 55-year-old woman who presented to clinic with complaints of severe, debilitating glare after a superotemporal laser peripheral iridotomy for narrow angle. She underwent keratopigmentation using black dye within a manual stromal pocket in the right eye. She noticed immediately after the procedure that she still had reduced but persistent glare. Despite a seemingly opaque corneal stromal tattoo on direct visualization, retro-illumination demonstrated areas with persistent light transmission due to patchy pigmentation coverage. She underwent a repeat corneal stromal tattoo procedure with brown dye. Immediate examination with retro-illumination at the time of the procedure demonstrated that the repeat corneal tattoo allowed no penetration of light. She reported complete resolution of her symptoms immediately afterwards as well as at her one-week follow-up.

The second case is a 60-year-old gentleman who presented with reports of glare and streaks of light after placement of a laser peripheral iridotomy in superior iris of the right eye in the setting of narrow angle glaucoma. On examination, he had a trans-illumination defect. He underwent corneal stromal tattooing over the superior iridotomy in the right eye with black ink placed in a manual stromal pocket. At follow-up, he reported persistent glare symptoms and retro-illumination highlighted regions within the corneal stromal tattoo where pigmentation was patchy and light transmittance remained visible. He underwent repeat corneal stromal tattooing in order to fully cover the region in the superior periphery with black dye. At one week post-procedure, he reported improvement in his symptoms but still noticed slight glare. Retro-illumination at this time demonstrated a persistent area of incomplete blockage of light in the superior periphery as well as a smaller area in the inferonasal midperiphery (Figure 1). The patient elected to undergo pupilloplasty (without revision of his inferonasal trans-illumination defect) with complete resolution of his symptoms after surgical repair of the iridectomy (symptoms continued to be resolved one month after surgical repair).

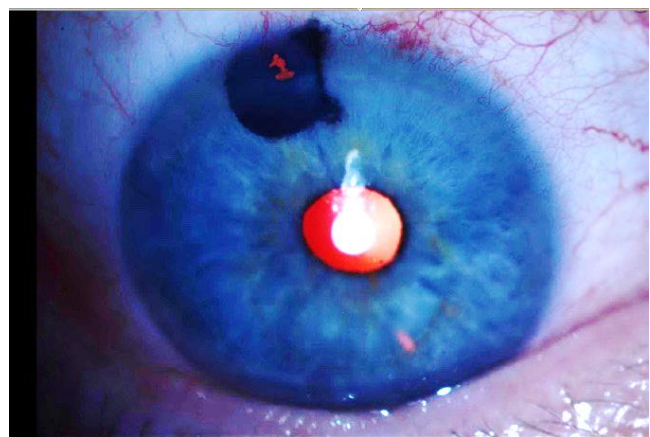


Figure 1
Slit lamp biomicroscopy of the patient's right eye after repeat corneal stromal tattoo with black ink, demonstrating a mostly opaque tattoo in the superior periphery with a region of persistent shine-through upon retro-illumination, and an unrelated inferonasal midperipheral trans-illumination defect.

Discussion

Corneal tattooing has been demonstrated to be effective in reducing complaints of photic phenomena such as halos, glare, and ghost images in patients with a peripheral laser iridotomy.⁶⁻⁸ However, corneal tattooing may fail to resolve symptoms. In this report, we highlight one potential cause for this failure by presenting two cases of persistent symptoms of glare from a peripheral laser iridotomy site after undergoing corneal stromal tattooing. The reason for these failures is believed to be inadequate coverage of the corneal stromal pocket with ink despite a seemingly opaque tattoo. Only after retro-illumination was utilized, were we able to highlight defects in the tattoo and to confirm adequate coverage after repeat keratopigmentation.

We propose applying retro-illumination during corneal tattooing as a method to reduce failure rate. If retro-illumination demonstrates defects in the pigmentation, we propose additional placement of dye in the corneal stromal pocket for complete obscuration of the defect. The use of retro-illumination immediately after the corneal tattooing procedure may further guide placement of pigmentation and enhance success rates of this method.

References

1. Roy N. Tattooing of the cornea. *Can Med Assoc J* 1938; 39: 436-8.
2. Islam N, Franks W. Therapeutic corneal tattoo following peripheral iridotomy complication. *Eye* 2006; 20: 389-90.
3. Garrido-Hermosilla A, Angeles-Figueroa R, Gessa-Sorroche M. Surgical intrastromal keratopigmentation using tattoo ink. *Arch Soc Esp Oftalmol* 2014; 89: 286-9.
4. Burris T, Holmes-Higgin D, Silvestrini T. Lamellar intrastromal corneal tattoo for treating iris defects (artificial iris). *Cornea* 1998; 17: 169-73.
5. Miller G, Gupta N, Howarth D, et al. A tale of two corneal tattoos. *Can J Ophthalmol* 2009; 44: 470-2.
6. Alio J, Rodriguez A, Toffaha B. Keratopigmentation (corneal tattooing) for the management of visual disabilities of the eye related to iris defects. *Br J Ophthalmol* 2011; 95: 1397-1401.
7. Faschinger C. Corneal tattoo with dysphotopsia after iridotomy: worth a chance! *Spektrum Augenheilkd* 2015; 29: 118-22.
8. Ricardo J, Medhi J, Pineda R. Femtosecond laser-assisted keratopigmentation for the management of visual disabilities due to peripheral iridectomies. *J Glaucoma* 2015; 24: e22-4.